

# Primary hyperparathyroidism in pregnancy: surgical or conservative management?

Kate Evans\*, Bijay Vaidya\*\*

Departments of Diabetes & Endocrinology, \*Plymouth Hospitals NHS Trust and \*\*Royal Devon and Exeter Hospital, Exeter

## Overview

- Primary hyperparathyroidism uncommonly presents during pregnancy; initially the diagnosis may not be considered due to overlap between the symptoms of hypercalcaemia and “normal pregnancy”.
- It can be associated with maternal and foetal complications (see Figure 1)
- There are particular challenges for both diagnosis and treatment: the usual imaging sequence for adenoma localization cannot be used and there is little evidence base to guide decisions on treatment.
- We present 2 cases, comparing surgical versus conservative management strategies.

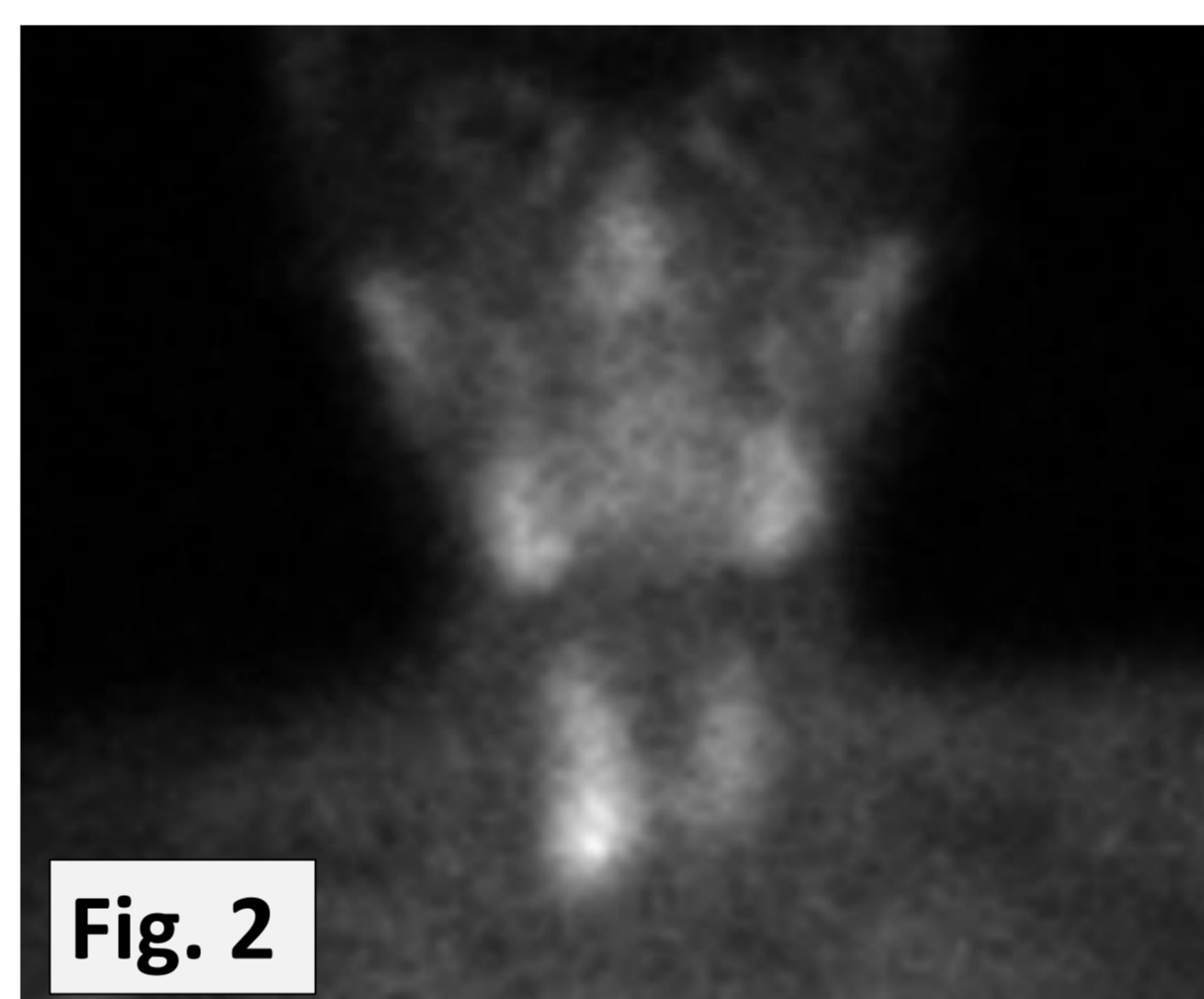
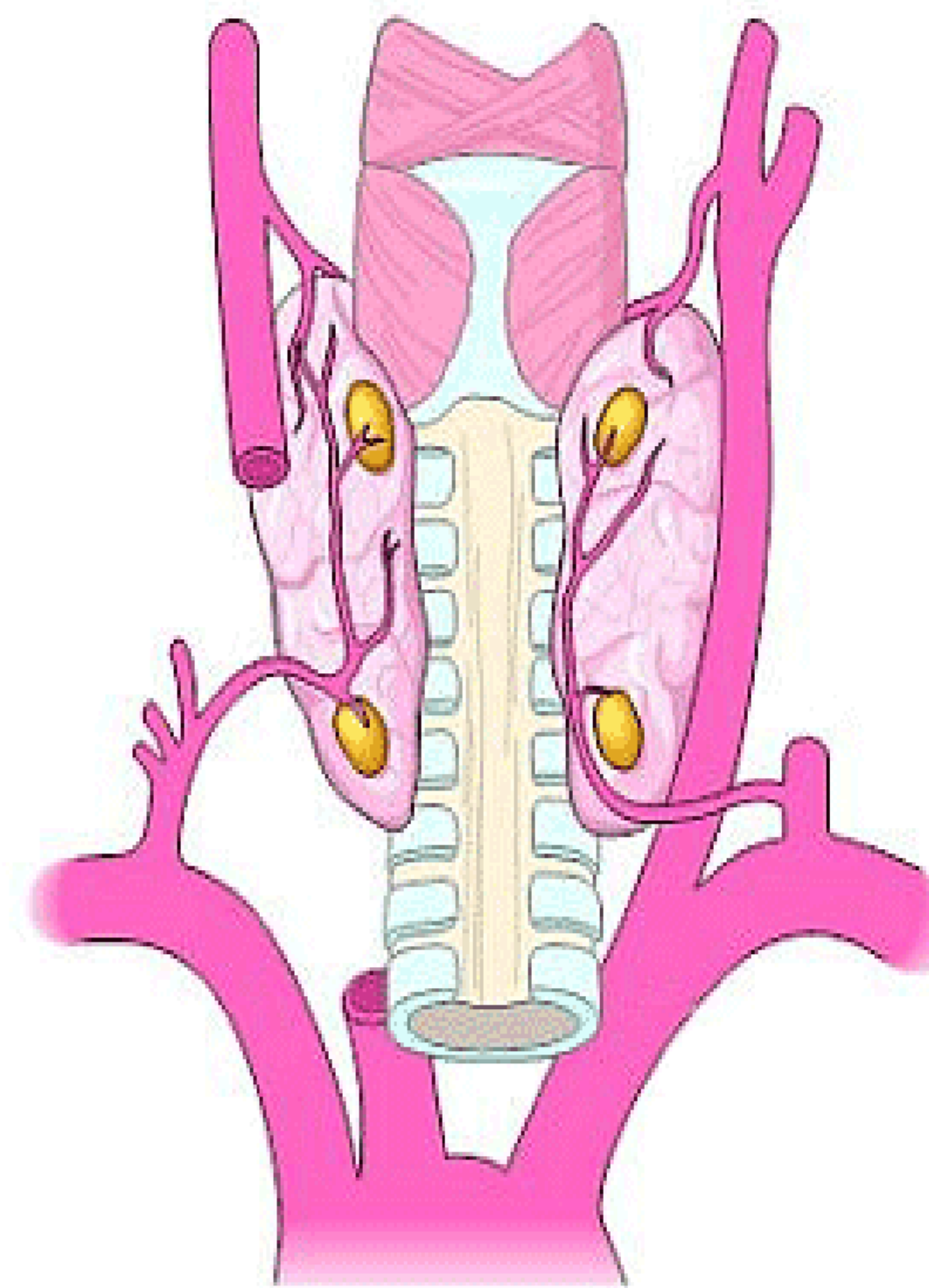
## Case 1:

**32 yr old woman with morbid obesity (BMI 50) presented with hyperemesis gravidarum at 17/40.**

- Investigation revealed unexpected marked hypercalcaemia: cCa 3.3mmol/l (NR 2.1 -2.55mmol/l), inappropriately elevated PTH at 10.4 pmol/l (NR 1.6-6.9pmol/l) and elevated urinary calcium:16.3mmol/24hrs (NR 2.5-7.5).
- MEN1 and RET genetic testing: no mutation found

## Management:

- She was admitted for IV rehydration; cCa fell to <3mmol/l.
- Ultrasound localised a right inferior parathyroid adenoma.
- Given cCa>3mmol/l and extreme symptoms, surgical treatment was preferred.
- She had parathyroidectomy in the 2<sup>nd</sup> trimester with perioperative frozen section confirming parathyroid tissue.
- Postoperatively, calcium fell to 2.35mmol/l and has remained in the normal range and PTH fell to 0.8 pmol/l
- Due to the development of hypertension and proteinuria, she was delivered by caesarean section at 36/40 of a healthy male infant weighing 3.19kg.
- Postnatal cCa 2.25mmol/l, PTH 1.2 pmol/l.



## Figure 1

### Potential complications of Primary Hyperparathyroidism during pregnancy

#### Maternal:

- Miscarriage
- Hyperemesis
- Hypercalcaemic crisis
- Nephrolithiasis
- Pancreatitis
- Pre-eclampsia

#### Foetal / Neonatal:

- Intrauterine growth retardation
- Stillbirth
- Low birth weight
- Preterm delivery
- Neonatal tetany and hypocalcaemic seizures

## Key points:

- Avoid radioisotope scanning during pregnancy.
- Screen for MEN and exclude FHH.
- Minimally invasive parathyroid surgery may be possible with pre-operative ultrasound adenoma localisation.
- Surgical treatment if symptomatic/marked hypercalcaemia.
- An association between primary hyperparathyroidism and preeclampsia has been reported in few cases.
- If surgery is planned, this should be preferably be carried out during second trimester. Reports of successful surgery in 3<sup>rd</sup> trimester too.
- Conservative management may be safe as long as serum calcium is not markedly elevated (<3mmol/l).
- Multidisciplinary discussion and patient counselling is important for successful outcome

## Case 2:

**33 year old woman with well controlled type 1 diabetes (HbA1c 36mmol/mol) presented at 33/40 feeling excessively tired, with polyuria and polydipsia.**

- On investigation: raised serum calcium 2.78mmol/l (NR 2.05-2.55), inappropriately raised PTH 9.1 pmol/l (1.6-6.9) and elevated urinary calcium 16.5mmol/24 hrs (2.5-7.5) Low Vitamin D 13 nmol/l.
- Diagnosed with primary hyperparathyroidism & Vit D deficiency
- No parathyroid adenoma found on neck ultrasound
- No nephrolithiasis on renal tract ultrasound

## Management:

- After multidisciplinary discussion, conservative management was planned for the duration of pregnancy
- Vitamin D replacement was started, and she was advised to keep well hydrated.
- Serum calcium varied between 2.69–3.0 mmol/l
- She delivered a healthy baby boy: his serum calcium was initially high but asymptomatic, and normalised by day 2.
- Postnatal Sestamibi scan showed increased uptake in right lower pole (**Fig.2**)
- Successful parathyroidectomy was carried out post-partum with normal post-operative serum calcium and PTH.
- Genetic testing for MEN1 negative

## Further reading:

Pregnancy outcomes in women with primary hyperparathyroidism. Abood A, Vestergaard P. Eur J Endocrinol. 2014 Jul;171(1):69-76.

Primary hyperparathyroidism in pregnancy. Kaminecky et al. Ann Endocrinol (Paris). 2016 Jun;77(2):169-71

Parathyroidectomy in Pregnancy. Walker et al. Gland Surgery 2014; 3(3):158-164