

The weekly injection: A practical solution to an old crisis

Arshiya Tabasum¹, Peter Taylor^{1,2}, John Geen¹, Gina Sanki¹, Brian Tennant¹, Andrew Aldridge¹, Onyebuchi Okosieme^{1,2} and Gautam Das¹
¹ Department of Diabetes and Endocrinology, Prince Charles Hospital, Cwm Taf University Health Board, Merthyr Tydfil
² Institute of Molecular and Experimental Medicine, Cardiff University School of Medicine, Cardiff.

Background

Myxedema coma is a rare and severe life threatening clinical consequence of untreated hypothyroidism. It has a high mortality rate of > 50% if not diagnosed and treated promptly. (1)

Case Presentation

History

A 82-year-old female was admitted with confusion and in a semi-comatose state after being found on the floor by her relatives. She was known to have hypothyroidism (2006) and was on levothyroxine 75 µg once a day.

Examination

She was unkept, confused, bradycardic and hypothermic. Her GCS was low and she was barely arousable. Her general appearance reflected gross features of self neglect.

Thyroid profile : (on admission)

TSH >100 mU/L and FT4 - 1.4 pmol/L .

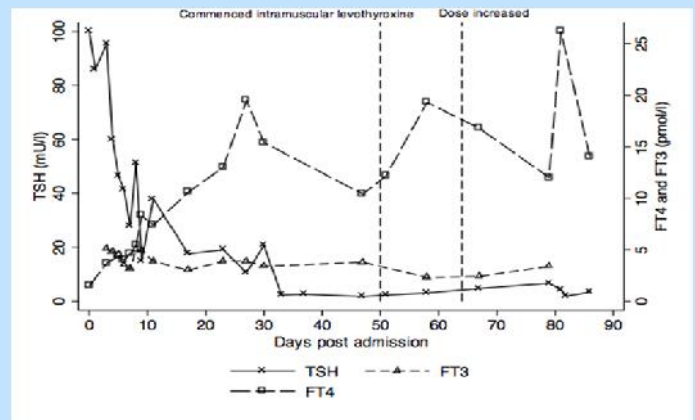
Treatment

The patient's clinical features and thyroid profile was suggestive of **Myxoedema coma**. She was resuscitated and was commenced on IV Hydrocortisone, IV Liothyronine and Levothyroxine via NG tube.

Clinical Course

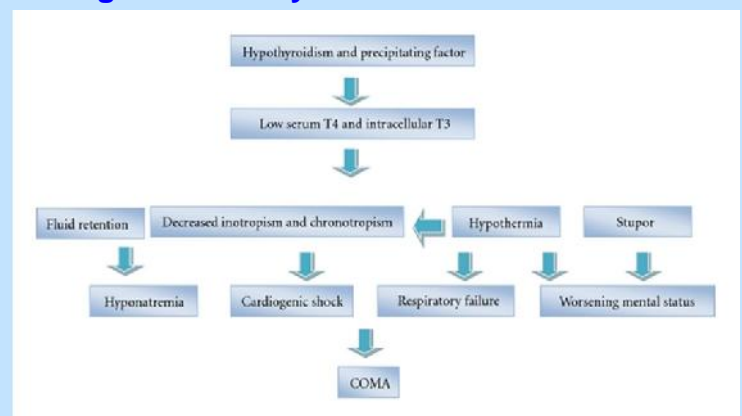
After an initial recovery she deteriorated over the next few days. She developed pulmonary oedema consequent to an acute coronary syndrome (troponin- 780 ng/L) and was managed in the CCU and then in ITU where she needed diuresis, inotropic support and assisted ventilation. A CXR revealed cardiomegaly, pulmonary congestion and an echocardiogram showed impaired diastolic function. Interestingly, a review of an earlier TFT's (11 months ago) showed a TSH of 27.21 mu/L and FT4 of 12.1 pmol/L indicating a picture of poor compliance/inadequate dose. A dose adjustment was advised but it never happened. She recovered gradually with IV liothyronine and oral thyroxine preparation under close supervision. Her TFT's improved and her FT3 was maintained in the lower half of the reference range. Her TFT's were monitored and reviewed regularly (chart) . After a step down , she was maintained on IV liothyronine in the wards as it became apparent that she was pouching and spitting out her levothyroxine tablets . She was then managed with IM levothyroxine (200 mcg/week) with serial monitoring. Her TFT's stabilized and she made good progress with no adverse effects and her overall performance and cognitive function improved significantly.

Figure 1. Impact of treatment on TFT's



Discussion

Pathogenesis of Myxoedema Coma



Management

1. To be managed in an ITU set up with CVP monitoring and ventilatory support (if needed)
2. Prompt correction of hemodynamic instability and correction of electrolytes
3. IV steroids (hydrocortisone)
4. Thyroid Hormone replacement – IV/NG levothyroxine AND/OR IV liothyronine
5. After recovery (in non – compliant patients) – Either weekly or twice weekly oral thyroxine (supervised) or use of intramuscular levothyroxine with serial monitoring of TFT's . The IM dose is usually lower and 50-75% of the oral dose.

Conclusion

This report highlights the issues and complexities relating to the management of Myxedema coma/crisis. It also emphasizes the potential role of the use IM levothyroxine in individuals with poor absorption or compliance in whom the risk of recurrence is very high.

Reference:1. Vivek Mathew et al. Myxedema Coma: A New Look into an Old Crisis. J Thyroid Res. 2011; 2011: 493462.